

CASE REPORT

David Sweet,¹ D.M.D., Ph.D. and Gary G. Shutler,² Ph.D.

Analysis of Salivary DNA Evidence from a Bite Mark on a Body Submerged in Water

REFERENCE: Sweet D, Shutler GG. Analysis of salivary DNA evidence from a bite mark on a body submerged in water. *J Forensic Sci* 1999;44(5):1069–1072.

ABSTRACT: A female body was recovered after approximately 5.5 h in a river with slow-moving current. On the victim's right breast, a patterned injury was discovered and determined to be from human adult teeth. Evidence was collected according to established techniques including recovery of saliva from the bite mark area despite the body being found submerged in water. DNA analysis by PCR using polymorphic STR markers revealed a DNA profile of mixed origin. In addition to the victim's DNA profile, a genotype contribution from the perpetrator was identified as a minor component. The DNA typing results from the bite mark correlated with the DNA typing results obtained from other biological trace evidence identified from the victim's genital samples. The bite mark and the DNA evidence were used to screen suspects and played an important role in obtaining resolution of this case. Consequently, it is advisable that investigators routinely swab for salivary DNA in bite mark cases, even when the amount is thought to be minimal.

KEYWORDS: forensic science, forensic dentistry, DNA typing, saliva, human bite mark, polymerase chain reaction, short tandem repeats, case, submersion, postmortem, VWA, F13A01, FES/FPS, D21S11, FGA

Human bite mark evidence is often crucial in establishing that two people were in violent contact with each other at the scene of a crime. The teeth may be used as an offensive weapon during an attack, or they may be used in self-defense. Obviously, the scope of bite mark injuries on human skin is broad depending upon the circumstances, such as the amount of force generated by the teeth, the time of interaction between the teeth and skin, and the type of tissue bitten, as well as the site on the body. Teeth may produce various types of traumatic injuries, including erythema, contusion, abrasion, laceration, or tissue avulsion (1).

Depending upon the degree to which the features and characteristics of the teeth are recorded on the skin in the bite mark, this physical evidence can be compared to the teeth of any suspects in an attempt to determine the origin of the marks. Many authors have reported problems with bite mark analysis (2,3). These are primar-

ily based on the fact that skin is elastic and distortable and may not be a good impression medium. Concern has also been raised with respect to the various comparison methods in use (3), production of transparent comparison overlays (4), and the level of experience and skill of the expert (5).

Consequently, many investigators now consider the saliva deposited during biting, especially the DNA present in saliva, to be an important alternative focus in bite mark analysis. The sensitivity of PCR-based DNA typing which allows minute traces of DNA evidence to be analyzed, even when it is partially degraded, is seen as a significant advantage. DNA from the cellular material present in the biter's saliva can be differentiated from the DNA of the victim's skin (6).

This case report demonstrates the application of laboratory methods previously reported by the author (DJS) to an actual forensic case. What is remarkable about this case is that, after the bite mark occurred, the victim's body was deposited in a river for a period of approximately 5.5 h before it was discovered. Despite this submersion in a slow-moving current, sufficient DNA was recovered from the bite area to detect a genotype contribution from the perpetrator.

Case Circumstances

Two 16-year-old females were walking home in a residential neighborhood at approximately midnight after leaving a party. A man with a baseball bat who demanded that they undress accosted them. He attempted to sexually assault the two friends after striking them with the bat. One female was able to gain control of the weapon and hit the attacker while his attention was turned to the other female. As a result, she was severely beaten and suffered head, arm, and hand injuries. She was left at the scene unconscious. Several hours later, she regained enough consciousness to proceed to a nearby hospital where she received emergency care. The body of the second female was discovered the next morning in a nearby river. She had suffered extensive head injuries and had been sexually assaulted. Shoe and heel marks were found on her naked body. An autopsy determined she died as a result of drowning.

At the time of postmortem examination, a patterned injury was discovered on the victim's right breast (see Fig. 1). A forensic odontologist determined that human adult teeth had caused the injury. The forensic significance of the physical evidence was estimated to be moderately high. Evidence was recovered according to established techniques, including extensive photographic documentation and accurate impressions of the skin surface. Sali-

¹ Director, Bureau of Legal Dentistry, 146 - 2355 East Mall, Vancouver, BC Canada V6T 1Z4.

² IC Biology Section, Forensic Laboratory Winnipeg, Royal Canadian Mounted Police, 621 Academy Road, Winnipeg, MB Canada R3N 0E7.

Received 28 Sept. 1998; and in revised form 3 Dec. 1998; accepted 3 Dec. 1998.

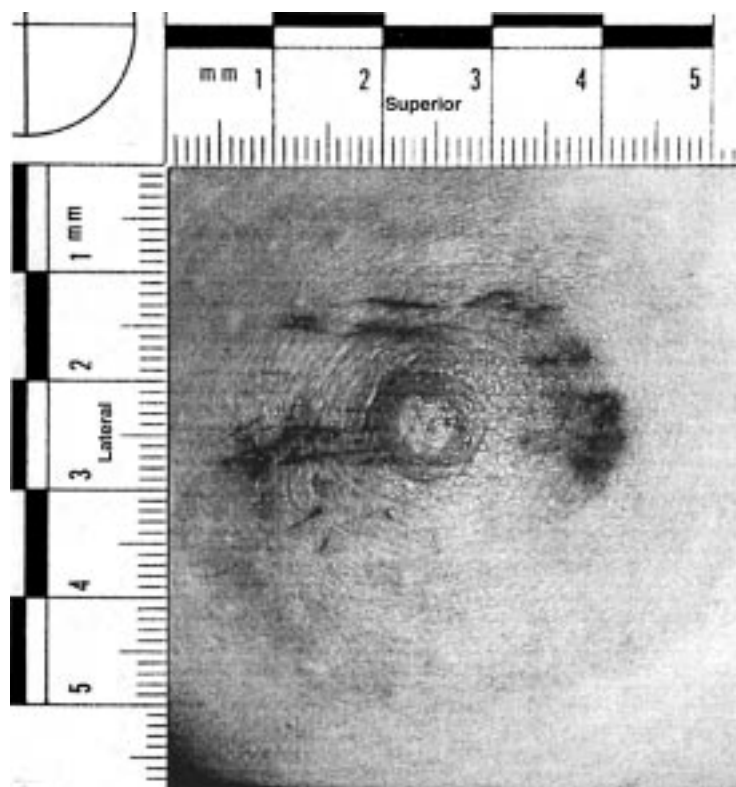


FIG. 1—Bite mark injury on victim's right breast.

vary swabs of the area had been taken at the time of discovery of the bite mark as part of the forensic pathologist's standard operating procedure. The pathologist also recovered biological evidence in the form of post-coital swabs containing epithelial and sperm cells.

A male person, who was in possession of details of the crime and the victim's injuries that had not been released to the public, began taunting police through a series of telephone calls. The surviving victim following her recovery produced a composite drawing of the suspect from a description, but the suspect eluded police for several months. The grave marker from the deceased victim's grave was stolen, and later found defaced. The suspect indicated in more telephone calls to police that he would kill again. A note attached to a tool was tossed through the window of a home. This contained information about other attempted sexual assaults in the area and the police determined that the suspect was a serial rapist.

During the course of a seven-month investigation, police investigated 34 suspects. Warrants were executed to obtain DNA reference samples from each suspect. Dental exemplars were seized from three of these suspects. The forensic odontologist completed a comparison of the suspects' teeth to the bite mark. These three suspects were excluded as the cause of the bite mark found on the victim. DNA analysis subsequently confirmed that the genotypes of these suspects were not the same as the genotype of the biological evidence recovered from the victim's body.

An informant told police that she recognized the voice recorded during taunting telephone calls and released during a media campaign to find the killer. This information led to the arrest of a resident in the community who was not previously considered by the police. Fingerprint evidence from the note tossed through the window matched the suspect's fingerprints. Using this information to

illustrate probable cause, dental exemplars and a DNA sample were seized under the provisions of a general warrant.

Material and Methods

A comprehensive measurement and pattern analysis was completed on the physical evidence. Dimensions of the individual tooth marks in the injury on the breast were compared to the dimensions of the suspect's teeth. Life-sized and twice life-sized transparent comparison overlays were produced from the suspect's dental study casts using a computer-based technique (4). These were compared to similarly enlarged photographs of the bite mark.

The procedure used by the forensic pathologist to recover saliva from the bite mark on the victim's right breast was the traditional serological procedure using a sterile, cotton swab moistened with sterile water. The tip of the swab was rolled over the surface of the bite mark to wash the saliva from the skin surface. A total of four swabs were removed from the various aspects of the bite mark injury. A control sample was recovered from the surface of the other breast. The swabs were air-dried at room temperature while enclosed in cardboard evidence boxes.

The post-coital samples were recovered using dry, sterile cotton swabs. Samples were recovered from: a) high in the vaginal vault, b) the vulva, including the labia majora and labia minora, c) the mons pubis, d) the rectum, and e) the oral cavity. These swabs were air-dried at room temperature while enclosed in cardboard evidence boxes.

The breast and vaginal swabs were submitted to the Royal Canadian Mounted Police Forensic Laboratory for analysis. The breast swabs were extracted using a procedure previously described (7). Briefly, swab heads were placed in individual Spin-EASE extrac-

tion tubes (GIBCO-BRL, Grand Island, NY, model 10238-012) and incubated at 56°C overnight in 400 µL of stain extraction buffer (to 160 mL filtered autoclaved distilled water add 1.0 mL 2M Tris (pH 8.0); 4.0 mL 0.5M Na₂EDTA-2H₂O; 20.0 mL 20% SDS; and 1.17 g NaCl) and 10 µL Proteinase K (20 mg/mL). The swab heads were transferred to a Spin-EASE basket and centrifuged at 13,000 xg for 1–2 m. The stain extract was purified using a three-step organic extraction (7) and concentration on Microcon-100 filters (Amicon/Millipore Corp., Bedford, MA).

Genomic DNA was extracted from the post-coital swabs using a differential extraction procedure to yield three fractions as described previously (7). Briefly, the F3 fraction contains predominantly male DNA from spermatozoa. The F3 pellet is incubated at 37°C for 2 h in 150 µL TNE; 50 µL 20% Sarkosyl; 40 µL 0.39M DTT; 150 µL filtered autoclaved distilled water; and 10 µL Proteinase K (20 mg/mL). The DNA from this fraction is purified by organic extraction and Microcon-100 concentration.

The sample extracts were quantified by slot-blot hybridization and ethidium bromide stained agarose mini-gel electrophoresis, also known as yield gel (8). Amplification of STRs HUMvWA, HUMF13A1, and HUMFES/FPS (multiplex STR2) have been described previously (9,10). Amplification and detection for gender determination and STRs HUMD21S11 and HUMFGA (multiplex STR1) have also been previously described (9,11). All amplifications were completed in a GeneAmp[®] PCR System Perkin Elmer 9600 thermal cycler (PE Applied Biosystems, Foster City, CA). Samples were loaded and run on an ABD 373A sequencing instrument (PE Applied Biosystems, Foster City, CA) for approximately 3 h set at 1250 v, 85 mA, 85 W for STR2 or 5 h set at 1800 v, 85 mA, and 85 W for STR1. Allele sizes were estimated using the local Southern method from GeneScan[™] Analysis v.1.2.1 and Genotyper[™] Analysis software (PE Applied Biosystems, Foster City, CA).

Results

Through physical comparison of the dental exemplars to the bite mark evidence, it was determined that the suspect's teeth were the probable cause of the bite mark on the victim's breast. The sizes, shapes, and configuration of the teeth and dental arches corresponded to the sizes, shapes, and configuration of the injury pattern well enough to conclude that most people in the population could not leave such a mark (12).

The amount of DNA recovered from each of the four swabs taken from the bite mark on the right breast was less than the lowest DNA reference standard (1.5 ng/µL). This was confirmed with a yield gel, which showed ≤5 ng DNA in the extract. Consequently, the extracts from individual swabs were pooled into a common exhibit for PCR-based typing. The amount of DNA recovered from the semen-enriched or F3 fraction of the post-coital swab was 25 ng/µL (≤50 ng HMW DNA on yield gel).

The DNA typing profile obtained from the pooled bite mark swabs was indicative of a mixed sample consistent with having originated from the victim (major component) and the suspect (minor component). The profile from the minor component could only be distinguished (no shared peaks) at one locus, HUMTH01, and partially distinguished (three peaks, one shared) at another locus, HUMvWA. Assuming that the major component was from the deceased, the estimated frequency of the occurrence of the minor component in the Canadian Caucasian population is 1:220.

Discussion

According to the Bite Mark Guidelines and Standards of the American Board of Forensic Odontology (ABFO) there are five

possible conclusions from bite mark physical comparisons: a) positive identification, b) probable identification, c) possible identification, d) insufficient data to reach a conclusion, and e) negative identification (exclusion) (12). In the case reported here, the conclusion was a probable identification. This result was confirmed by independent, blind testing by three forensic odontologists according to ABFO recommendations.

The strategy developed by the odontologist in reporting his conclusions was significant. In each case (four suspects in total), when conclusions were reached following physical comparison of the bite mark evidence, the bite mark report and conclusions were submitted in writing prior to the police or odontologist receiving the DNA conclusions. This protocol is recommended since it prevents any perception of bias and ensures that the conclusions reached by the odontologist are independent.

Recovery and PCR-based analysis of DNA from saliva deposited on human skin using the double swab technique has been previously described (6,13). It has been reported that this evidence is stable on intact skin for at least 60 h following deposition (14). In the case reported here, the fact that genomic DNA of sufficient quantity and quality to perform STR analysis was recovered after the bitten area was submerged in water is very significant. At the time of discovery, considerable thought was given to whether recovery of salivary evidence should be attempted at all. It was decided that standard operating procedures (12) should be followed and the area was swabbed using the forensic pathologist's routine procedure.

The quantity of DNA recovered from the bite mark using the single swab technique was relatively low. It is unclear whether this is due to the low amount of trace evidence present or the fact that the double swab technique was not used (13). Nevertheless, it is clearly advisable for investigators to routinely swab for salivary DNA in bite mark cases, even when the amount of evidence available is thought to be minimal.

The suspect was identified as the probable biter through analysis of the bite mark physical evidence. Thirty-three other suspects were excluded as the cause of the bite mark using the DNA evidence. The prime suspect's DNA profile was consistent with that of the saliva depositor. This evidence was in agreement with the DNA typing results from the post-coital samples where the semen donor's DNA profile matched the suspect's profile at six STR loci (results from RFLP analysis were also in agreement; data not shown). This evidence was critical in the resolution of the case at trial.

Acknowledgments

The assistance of D. O'Keefe and M. Thomson, Biology Section, Royal Canadian Mounted Police Forensic Laboratory, Vancouver, BC and Dr. S. Carlisle, forensic pathologist, Royal Columbian Hospital, New Westminster, BC is gratefully acknowledged.

References

1. Sweet D. Human bite marks: examination, recovery and analysis. In: Bowers CM, Bell GL, editors. *Manual of Forensic Odontology*, Colorado Springs: American Society of Forensic Odontology, Third Edition, 1997; 148–69.
2. Whittaker DK. Some laboratory studies on the accuracy of bitemark comparison. *Int Dent J* 1975;25:166–70.
3. Sweet D, Bowers CM. Accuracy of bite mark overlays: a comparison of five common methods to produce exemplars of a suspect's dentition. *J Forensic Sci* 1998;43(2):362–7.
4. Sweet D, Parhar M, Wood RE. Computer-based production of bite mark comparison overlays. *J Forensic Sci* 1998;43(5):1046–51.

5. Rothwell BR. Bite marks in forensic odontology: fact or fiction? In: Worthington P, Evans ER, editors. *Oral and maxillofacial surgery*, Philadelphia: WB Saunders, 1994;588–600.
6. Sweet D, Lorente JA, Valenzuela A, Lorente M, Villanueva E. PCR-based typing of saliva stains recovered from human skin. *J Forensic Sci* 1997; 42(3):447–51.
7. Royal Canadian Mounted Police, Biology Section Methods Guide, Chapter III.1, Isolation of DNA from body fluid stains. Revised: October 16, 1992.
8. Wayne J, Presley L, Budowle B, Shutler G, Fourney R. A simple and sensitive method for quantifying human genomic DNA in forensic specimen extracts. *BioTechniques* 1989;7(8):852–5.
9. Royal Canadian Mounted Police, Biology section methods guide, Chapter III.3, Fluorescent multiplex amplification of short tandem repeat (STR) loci. Revised: March 24, 1995.
10. Shutler GG, Gagnon P, Verret G, Kalyn H, Smith S, Johnston E, et al. Case report: removal of a PCR inhibitor and resolution of DNA STR types in mixed human-canine stains from a five year old case. *J Forensic Sci* 1999; 44(3): in press.
11. Fregeau CJ, Fourney RM. DNA typing with fluorescently tagged short tandem repeats: a sensitive and accurate approach to human identification. *BioTechniques* 1993;15:100–19.
12. American Board of Forensic Odontology. ABFO bite mark methodology guidelines. In: Bowers CM, Bell GL, editors. *Manual of Forensic Odontology*, Colorado Springs: American Society of Forensic Odontology, Third Edition 1997;334–7.
13. Sweet D, Lorente M, Lorente JA, Valenzuela A, Villanueva E. An improved method to recover saliva from human skin: the double swab technique. *J Forensic Sci* 1997;42(2):320–2.
14. Smith BC, Holland MM, Sweet D, DiZinno JA. DNA and the forensic odontologist. In: Bowers CM, Bell GL, editors. *Manual of Forensic Odontology*, Colorado Springs: American Society of Forensic Odontology, Third Edition 1997;283–98.

Additional information and reprint requests:

Dr. David Sweet
146 - 2355 East Mall
Vancouver, BC Canada V6T 1Z4
Phone: (604) 822-8822; Fax: (604) 822-8884
E-mail: dsweet@interchange.ubc.ca